

VIDEO ASSISTED THYROIDECTOMY

C. Bradea

First Surgical Clinic, „St. Spiridon” Hospital Iași
„Gr.T. Popa” University of Medicine and Pharmacy Iași

VIDEO ASSISTED THYROIDECTOMY (Abstract): Video assisted techniques were documented by M. Gagner (1996 – video assisted parathyroidectomy), Henry (1999), Shimizu (1999), Ohgami (2000), Miccoli (2000 – video assisted parathyroidectomy and thyroidectomy). The advantage of this kind of surgery: aesthetics i.e. trying to make only small scars on the neck. Our first case of video assisted thyroidectomy was a female 50 years of age, with multinodular goiter, nodules of 2-3 cm in each lobe, admitted in our clinic in December 2008. History of the disease: 9 years; treatment: hormones pills. The refractive thyroid goiter became surgical in the last four years. The intervention was delayed because of pulmonary tuberculosis the patient suffered from. The video assisted technique is inspired from Websurg site (Miccoli technique, 2007), modified by the author. We started with general anesthesia, patient lying, without hiper extension of the neck. The skin incision was on midline of the neck, 15 mm long, horizontal, at 2 cm above the inferior limit of the neck, with electric scalpel. By this skin incision we entered the thyroid space gland with classical instruments; then we introduce a 10 mm, 0 degree telescope, together with a 5 mm Ligasure grasp. After coagulation and section with Ligasure, the superior thyroid pedicle, the right thyroid lobe was dissected all around. Finally, we extracted the right thyroid lobe and then we severed with Ligasure the inferior right thyroid pedicle. The same procedure was used on the left side; it needn't any drainage; the closure was anatomically tipical. The evolution was uneventful. The histopathological exam result was chronic Hashimoto thyroiditis. Conclusions: Video assisted thyroidectomy can be considered feasible and safe and allows for an excellent cosmetic result and has possible new promising indications such as prophylactic thyroidectomy. Not all patients are eligible for this procedure, but in selected cases it can be a valid option for the surgical treatment of thyroid diseases.

KEY WORDS: VIDEO ASSISTED SURGERY, VIDEOSCOPIIC SURGERY SKILL, SELECTED PATIENTS.

Correspondence to: Costel Bradea, MD, PhD; Assoc. Professor of Surgery, First Surgical Clinic, „St. Spiridon” Hospital Iași, Independenței Street No. 1, 700111, Iași, Romania; e-mail:costelbradea@yahoo.com*

BACKGROUND

From Kocher neck incision, along years, the surgeons tried to make smaller and smaller incisions because, in general, the patients are females. The aesthetic result of the operation has always been an important aspect for them. The first video assisted surgical techniques started with M. Gagner who made the first a parathyroidectomy, in 1996. Then, other authors, Henry, Miccoli, Oghami, Shimizu, stated that videoresection of nodular goiters is feasible with good results on selected patients (without gigantic goiters).

CASE REPORT

A 50 year old female with multinodular goiter, with nodules of 2-3 cm at echography, in both thyroid lobes was admitted in our clinic. The hystory of the disease was of 9 years with medical treatment;in the last 4 years the goiter was refractive to the

* received date: 10.01.2009

accepted date: 20.01.2009

hormonal pills. The surgical intervention was delayed because of a pulmonary tuberculosis, treated in a clinic of pulmonary diseases. The general cardio-pulmonary and endocrine status was normal before the surgical intervention.

Our source of inspiration was Miccoli's technique, 2007, modified by the author, for video-assisted thyroidectomy. We started with the patient lying, without neck hyperextension; general anesthesia is used. The incision at the skin was made by electric scalpel, 15 mm long, horizontal, at midline of the neck, at 2 cm above the inferior line of the neck. We entered by this incision with classical instruments the thyroid region; then we introduced a 10 mm 0 degree rigid telescop together with a 5 mm Ligasure device by the same incision. We dissected and transected with Ligasure device the superior right thyroid pedicle. Then we dissected all around the right lobe (Fig.1). The right thyroid lobe was extracted; by the same incision the inferior pedicle also with Ligasure is resected. On the left side, the same procedure was applied; no drainage was used; the incision was inclosed in layers. The evolution was uneventful. The histopathological exam result was chronic Hashimoto thyroiditis.

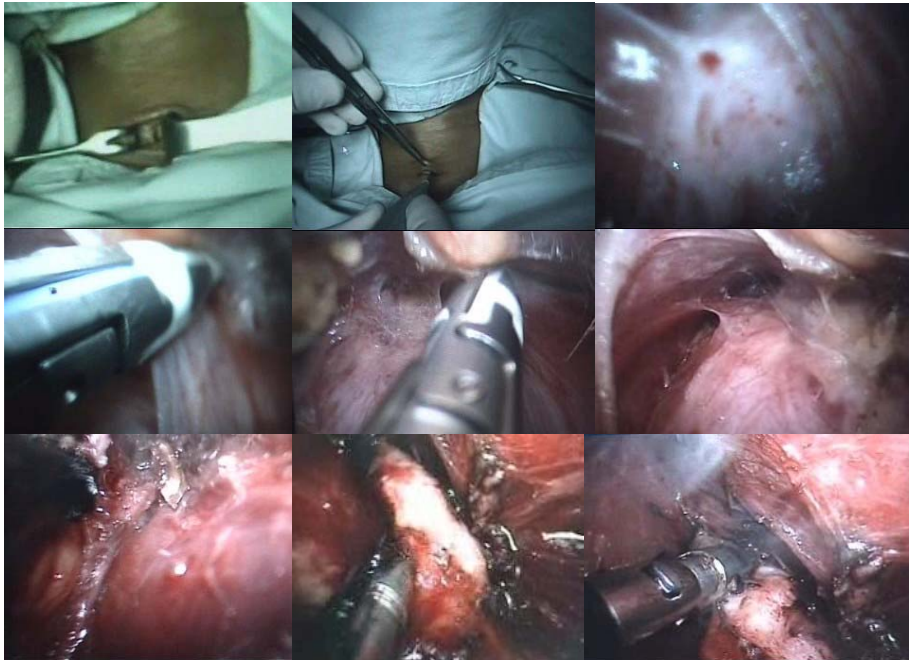


Fig. 1 Video assisted thyroidectomy
Intraoperative view

DISCUSSION

The thyroid gland begins to form on 17-th day of embryologic development between the first and second pharyngeal pouch, like an epithelial cord which penetrates the floor of the oral cavity and reaches the anterior side of trachea.

The thyroid gland consists of two lobes joined by an isthmus; it normally weights 20 grams; each lobe is of 2/3/5 cm. It is covered by strap muscles (sternothyroid and sterno-hioid). The recurrent nerves lie in the trachea-esophageal grooves. The arterial supply is from inferior and superior thyroid arteries, branches of external carotid and thyrocervical trunk. There are three thyroid veins: superior, middle and inferior whom drains in the internal jugular vein. The lymphatic drainage of the thyroid gland is

extensive. It consists of the central compartment (periglandular space) and a lateral one which are separated by the carotid sheath.

A number of details must be clarified before to start a video-operate: the size of thyroid gland, the adhesions after a previous operation or in our case of thyroiditis. During the operation we mustn't disrupt the capsule (the nodules are often suspected for a carcinoma). Small papillary carcinomas have been resected by this technique for two years (low risk carcinomas) with encouraging oncologic results [1]. The patient must have a normal thyroid gland function at the time of the operation.

The position of patient is supine with or without neck hyperextension. The incision must be made in an avascular zone, in a bloodless plane, with an electrocautery protected blade. Any bleeding is embarrassing and can block the operation. The retractions are very gentle on strap muscles and thyroid tissues. A 5 mm, 30 degrees telescope is ideal. Dissections are made with 2 mm atraumatic instruments. An aspirator-spatula is very important for direct washing and aspiration the smoke. The first vessel to be ligated is middle thyroid vein with 3 mm vascular clips, ultrasonic scalpel or Ligasure device. The tip of the electric scalpel must be carefully checked because a high temperature can damage the larynx and the recurrent laryngeal nerves. The inferior part of the thyroid gland is severed after it has been pulled out. No drainage is necessary. The wound is closed with absorbable sutures.

Complication rates are not high in video-thyroidectomy; is a safe operation with an acceptable time, following a short learning curve [1]. Video assisted total thyroidectomy is feasible with good oncologic and cosmetic results [2]. Large multinodular goiters are not eligible for minimal invasive surgery. The presence of lymph nodes and high risk carcinomas are a contra-indication for video resection [1]. It is possible to make prophylactic thyroidectomy to persons with Multiple Endocrine Neoplasia [3]. Total thyroidectomy for Multifocal Micropapillary Cancer is, also, feasible by video surgery [4].

The utilization of new devices for dissection, coagulation and division (harmonic, Ligasure) instead of the conventional technique as it ensures a dry field and a shorter operation time [5].

CONCLUSION

Video assisted thyroidectomy can be considered feasible and safe and allows for an excellent cosmetic result and has possible new promising indications such as prophylactic thyroidectomy. Not all patients are eligible for this procedure, but in selected cases it can be a valid option for the surgical treatment of thyroid diseases.

REFERENCES

1. Miccoli P. Minimally invasive video-assisted thyroidectomy. *WeBSurg's World University*, 2004-2007.
2. Ghorayeb BY. Minimally invasive video assisted thyroidectomy. *Otolaryngology Houston on line magazine*.
3. Skinner MA, Moley JA, Dille WG, Owzar K, Debenedetti MK, Wells SA Jr. Prophylactic thyroidectomy in multiple endocrine neoplasia type 2A. *The New England Journal of Medicine*. 2005; 353(11): 1105-1113.
4. American Thyroid Association. Total or near total thyroidectomy in patients with multifocal micropapillary cancer. *Cancer/Oncology*. 04oct2008.
5. United States National Institute of Health. Govern trials. Harmonic FOCUS versus Conventional Technique in Total Thyroidectomy for Benign Thyroid Disease.