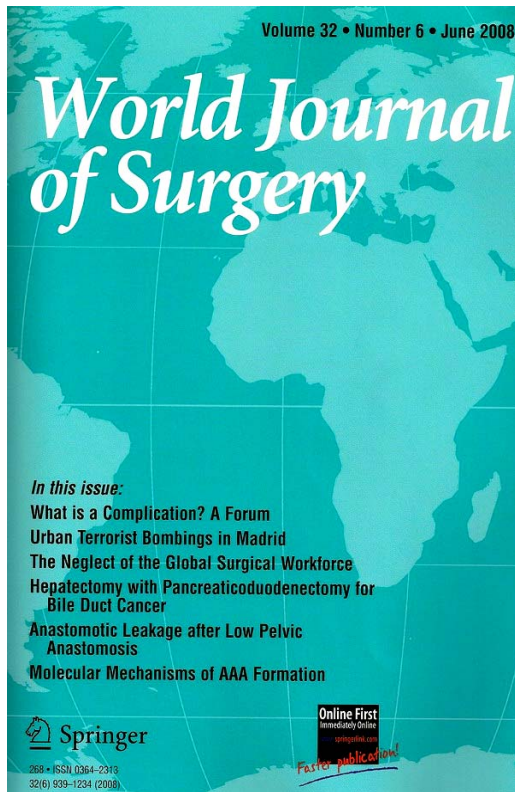


WORLD JOURNAL OF SURGERY

Vol. 32, nr. 6, 2008



The first part of journal is dedicated to surgical complications. A group of surgeon from ISS/SIC debate this important problem a our days who represent a challenging task.

A surgical complication is deemed to have occurred when there is an undesirable, but not necessarily unexpected or unpredicted, direct result of an operation, affecting the patient. This may occur even if the surgeon has performed the technical steps of the procedure in an exemplary manner and adopted standards of care that would be considered by peers to be appropriate for all circumstances concerning the particular patient and his or her pathology.

Dindo and your colleagues from ISS defined “negative outcome” by differentiating among complications, failure to cure, and sequelae. Complications were defined as “*any deviation from the normal postoperative course*” and a classification of complications by severity was proposed.

To avoid conflating surgical complications with sequelae, Sokol and Wilson can appeal to the notion of expectation: 1. A surgical complication (SC) is any undesirable and unexpected result of an operation. A scar need not be a complication. This will depend on whether it was expected. Our revised definition, however, does not specify the subject of the unpleasant result, hence a surgeon’s needlestick injury would constitute a surgical complication. The solution is to specify the recipient of the SC; 2. A SC is any undesirable and unexpected result of an operation affecting the patient; 3. A SC is any undesirable and unexpected result of an operation affecting the patient that occurs as a direct result of the operation; 4. A SC is any undesirable, unintended, and direct result of an operation affecting the patient, which would not have occurred had the operation gone as well as could reasonably be hoped. Although broadly agreeing with their assessment, Wigmore and Garden believe that they have potentially understated the role of the patient as a stakeholder in defining what constitutes a complication. Clearly a complication happens to someone and this is the patient and surely it is up to them to decide what does and what does not constitute a complication. Agarwal said it is vital to be able to differentiate between a sequel—an unavoidable accompaniment of a surgical procedure, and a complication. How does one take a balanced view of such diverse opinions? What would appear to be a complication to a group of expert surgeons in their collective wisdom may well be considered a “surgical

complication". In this surgeon's view, a surgical complication is an undesirable (or adverse) outcome of an operation. Gough said that the addition of other qualifying or clarifying descriptors is less important, and the concept of risk-adjustment should not be included. Risk-adjustment is relevant in the interpretation of the significance of a complication, but it is not appropriate in its definition. Gorra et al from Department of Surgery, Maine Medical Center, Portland, evaluate how survival of older patients with injuries differs by geographic region within the United States. The conclusions of this study was that the regional differences in risk-adjusted hospital survival for older patients with injuries are different from regional differences in 30-day survival. Hospital mortality as an outcome for older injured patients should be interpreted cautiously.

Keulers et al determine opinions of both surgeons and patients about issues of surgical information. Surgeons generally underestimate their patients desire for receiving extensive information prior to a surgical procedure of any complexity. Surgeons should develop strategies to bridge this informational mismatch.

In section ORIGINAL SCIENTIFIC RAPORT, VASCULAR SURGERY, Annambhotla et al present *Recent Advances in Molecular Mechanisms of Abdominal Aortic Aneurysm Formation* and Dick et al *Outcome and Quality of Life in Patients Treated for Abdominal Aortic Aneurysms: A Single Center Experience*.

In section UPPER GASTROINTESTINAL TRACT SURGERY Granderath et al, present *Laparoscopic Revisional Fundoplication with Circular Hiatal Mesh Prosthesis: The Long-term Results*. The conclusions of this study was that the laparoscopic refundoplication for primary failed hiatal closure with the use of a circular mesh prosthesis is a safe and effective procedure to prevent hiatal hernia recurrence for short- and mid-term follow-up. Johansson et al from department of Surgery, Lund University Hospital, Sweden present *Two Different Surgical Approaches in the Treatment of Adenocarcinoma at the Gastroesophageal Junction*. Adenocarcinoma at the gastroesophageal junction may be regarded as of esophageal or of gastric origin, and tumor removal may follow the principles of esophagectomy or extended gastrectomy. The tumors were categorized according to Siewert's classification (I, II, or III) of gastroesophageal junction tumors. Totally, 133 patients were operated on between 1990 and 2001. Ninety-six patients with type I (n = 67), II (n = 26), and III (n = 3) tumors underwent esophagectomy and gastric tube reconstruction, and 37 patients with type I (n = 5), II (n = 26), and III (n = 6) tumors underwent extended gastrectomy and long Roux-en-Y reconstructions. After adjusting for the independently significant impact factors—tumor stage, tumor dissection (R0–R2), and length of tumor free resection margins—they did not find any specific survival benefit associated with either of the two evaluated surgical approaches for tumor resection and reconstruction. The EORTC quality of life forms revealed good results as indicated by the functional scales and the symptom scales. In conclusions provided that adequate tumor dissection is performed, patients with adenocarcinoma at the gastroesophageal junction can be resected and reconstructed using the principles for esophagectomy or extended gastrectomy.

Wilhelm et al from department of Surgery, Technical University Munich, Germany analyzed clinicopathologic features and survival data of 93 consecutive patients undergoing a combined laparoscopic-endoscopic approach for gastric submucosal tumors. Combined laparoscopic-endoscopic "rendez-vous" procedures are easy to perform and offer a curative approach for almost all gastric submucosal lesions. The technique is associated with low morbidity and short hospitalization.

In section HEPATOPANCREATOBILIARY SURGERY McElroy et al present *Imaging of Primary and Metastatic Pancreatic Cancer Using a Fluorophore-Conjugated Anti-CA19-9 Antibody for Surgical Navigation*. In this study the authors investigate the use of a fluorophore-labeled anti-CA19-9 monoclonal antibody to improve intraoperative visualization of both primary and metastatic tumors in a mouse model of pancreatic cancer. A monoclonal antibody specific for CA19-9 was conjugated to a green fluorophore and delivered to tumor-bearing mice as a single intravenous (IV) dose. Intravital fluorescence imaging was used to localize tumor implants 24 h after antibody administration. Fluorophore-labeled anti-CA19-9 offers a novel intraoperative imaging technique for enhanced visualization of primary and metastatic tumors in pancreatic cancer when CA19-9 expression is present and may improve intraoperative staging and efficacy of resection.

From Japan, Division of Digestive and General Surgery, Niigata University, Wakai et al define the role of combined major hepatectomy and pancreaticoduodenectomy in the surgical management of biliary carcinoma and to identify potential candidates for this aggressive procedure. A retrospective analysis was conducted on 28 patients who underwent a combined major hepatectomy and pancreaticoduodenectomy for extrahepatic cholangiocarcinoma (n = 17) or gallbladder carcinoma (n = 11). Altogether, 11 patients underwent a Whipple procedure, and 17 had a pylorus-preserving pancreaticoduodenectomy. The median follow-up time was 169 months. Morbidity and in-hospital mortality were 82% and 21%, respectively. Overall cumulative survival rates after resection were 32% at 2 years and 11% at 5 years (median survival time 9 months). The median survival time was 6 months with a 2-year survival rate of 0% in 11 patients with residual tumor, whereas the median survival time was 26 months with a 5-year survival rate of 18% in 17 patients with no residual tumor. There were three 5-year survivors among the patients with no residual tumor. Combined major hepatectomy and pancreaticoduodenectomy provides survival benefit for some patients with locally advanced biliary carcinoma only if potentially curative (R0) resection is feasible. Patients with diffuse cholangiocarcinoma and gallbladder carcinoma with no bile duct involvement are potential candidates for this aggressive procedure.

Kanemitsu et al present *Prognostic Models for Predicting Death after Hepatectomy in Individuals with Hepatic Metastases from Colorectal Cancer*. Univariable analyses suggested that histology of the primary tumor, T stage of the primary cancer, number of metastatic lymph nodes associated with the primary cancer, lobar distribution of the hepatic lesions, number of hepatic tumors, size of the largest hepatic tumor, presence of extrahepatic disease before or at hepatic metastasectomy, the prehepatectomy CEA level, the interval between resection of the primary colorectal tumor and hepatic resection, presence of metastasis to hepatic hilar lymph nodes, and the width of the surgical margins were independently associated with survival after hepatectomy.

In section COLORECTAL SURGERY Frascio et al from Department of Surgery, University of Genoa, Italy, present *Surgery Stapled Transanal Rectal Resection for Outlet Obstruction Syndrome: Results and Follow-up*, Jung Wook Huh et al *Sphincter-Preserving Operations Following Preoperative Chemoradiation: An Alternative to Abdominoperineal Resection for Lower Rectal Cancer?*, Katoh et al *Surgical Resection of Stage IV Colorectal Cancer and Prognosis* and Nakamura et al present *Risk Factors for Wound Infection After Surgery for Colorectal Cancer*.

In section TRAUMA AND CRITICAL CARE, Kuhne et al from Department of Trauma, Reconstructive and Hand-Surgery, University Hospital Giessen and Marburg, Germany present the Emergency Transfusion Score (ETS), a measure that may allow important time and cost savings in the treatment of severely injured patients in the Emergency Room. Letoublon et al from Departement de Chirurgie Digestive et de l'Urgence, Hopital Michallon, Grenoble, France present *Delayed Celiotomy or Laparoscopy as part of the Nonoperative Management of Blunt Hepatic Trauma*. Nonoperative management (NOM) is considered standard treatment for 80% of blunt hepatic trauma (BHT). NOM is associated with some events that may require delayed operation (DO), usually considered a criterion of failure of NOM. This retrospective study suggest that BHT treated by NOM must be frequently reevaluated and that DO is an actual part of the so-called nonoperative treatment. The use of laparoscopic washing has to be proposed as soon as day 3 or 5 in patients with large hemoperitoneum and any sign of inflammatory response (fever, leukocytosis, discomfort, tachycardia).

This number close with sections RURAL AND INTERNATIONAL SURGERY and LETTERS TO THE EDITOR.

A. Vasilescu