

A CHOLELITHIASIC DOUBLE GALLBLADDER

B. Wani, G. Kolte, V. Rathod, A. Bhole

Department of Surgery, Acharya Vinoba Bhave Rural Hospital, Sawangi (Meghe),
Wardha, India

A CHOLELITHIASIC DOUBLE GALLBLADDER (Abstract): Double gallbladder is rare congenital anomaly. It is important to diagnose it preoperatively for which, ultrasound is the preferred modality of imaging. We report a case of 56 years old male patient who presented with recurrent upper abdominal pain and diagnosed as two cholelithiasic gallbladders for which we did cholecystectomy of both. We are reporting this case for its rare occurrence.

KEY WORDS: DOUBLE GALLBLADDER, VESICA FELLEA DIVISA, VESICA FELLEA DUPLEX

Correspondence to: Bhushan Wani, MD, Department of Surgery, Acharya Vinoba Bhave Rural Hospital, Sawangi (Meghe), Wardha 442004, India; email: drbnwani@yahoo.co.in*

INTRODUCTION

The gallbladder is one of the organs in our body most subject to anatomical variations; its abnormalities may be related to number, shape and position and may also affect the cystic duct and cystic artery. Double and triple gallbladders are rare congenital anomalies with an incidence for the double gallbladder of 1/3800–4000 patients [1]. All reports appeared in the literature are emphasizing the importance of pre-operative diagnosis, as if diagnosed during surgery; the per-operative location of the second gallbladder may be difficult or even be missed [2]. We report a case of double gallbladder in a fifty six years old male patient in whom the two cholelithiasic gallbladders were diagnosed and which is very rare.

CASE REPORT

A 56 years old male presented with pain in epigastric region without jaundice. History of nausea and vomiting was present. General examination revealed no abnormality. On abdominal examination mild tenderness was present in the epigastric region. Ultrasound of abdomen showed multiple calculi in the gallbladder lying in the gallbladder fossa with two stones in another pouch adjacent to it (second gallbladder), with normal cystic duct and Common Bile Duct (CBD). Cholecystectomy has been planned for the same. Intra-operatively dense adhesion of omentum over gallbladder was present. Both gallbladders were found to be fixed deeply in normal anatomical location. Two arteries supplying them separately with a common duct from them towards CBD was found. After ligation of two cystic arteries separately and a single cystic duct; a subtotal Cholecystectomy of elongated gallbladder (because of its deep adherence in fossa) with cholecystectomy of adjacent gallbladder was done (figure 1). Post-operatively patient recovered well and without any complications.

* received date: 21.08.2009

accepted date: 27.09.2009

DISCUSSION

Double gallbladder is a rare congenital anomaly with an incidence of one in 3800-4000 patients. Boyden had classified double gallbladders as, vesica fellea divisa or bilobed gallbladder, with single cystic duct and vesica fellea duplex or true duplication, with two different cystic ducts [1]. The true duplication which is more common further classified as, Y-shaped type (both cystic ducts unite before entering into the common bile duct) and the H-shaped type or ductular type (both cystic ducts entering separately into the common bile duct). The true duplication occurs due to bifurcation of gallbladder primordium in early embryonic life [1-3]. In our patient we found a complete duplication of the gallbladder with its own cystic artery and a common cystic duct entering the common bile duct.

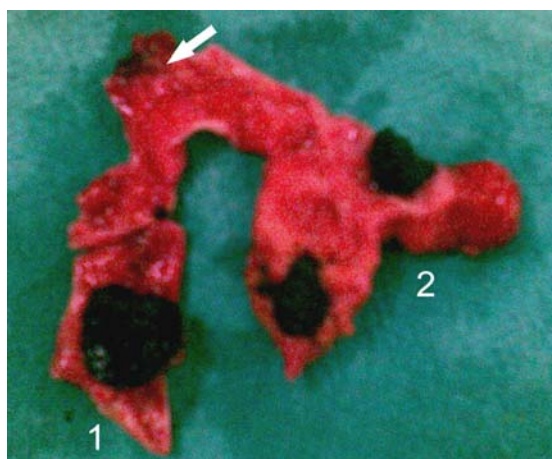


Fig. 1 Specimen of cholelithiatic double gallbladder,
The arrow showing, single cystic duct arising from Junction of both the gall bladders (1) Subtotal resection of GB with stone containing in it (2) Second GB with multiple calculi in it.

Double gallbladders do not present with specific symptoms and the incidence of disease in this gallbladder is similar to its normal variant, with gallstone formation being the commonest pathological process occurring in one or both lobes [4]. Preoperative evaluations of anatomical variations of the hepato-biliary tract is important in order to avoid potential damage to the duct system, as abnormal anatomy may be easily overlooked during surgery [2]. The various modalities like ultrasound, Oral cholecystogram (OCG), scintigraphy, ERCP, CT scan and MRI can be used to diagnose double gallbladder [5]. OCG and scintigraphy has limitations of restricted hepatobiliary uptake and excretion with a patent cystic duct; ERCP and PTC are the invasive procedures and will be used rarely. Thus ultrasound imaging is the modality of choice, with a high sensitivity and specificity. However CT scan and MRI are the nonvasive modality and can be used to delineate the anatomy [2]. The differential diagnosis of double gallbladder includes; gallbladder fold, focal adenomyomatosis phrygian cap, intraperitoneal fibrous (Ladd's) bands, choledochal cyst, pericholecystic fluid and gallbladder diverticulum [4]. In symptomatic patient, cholecystectomy is recommended with the excision of both the gallbladder even if the disease is present only in one lobe [2,6].

Complete preoperative evaluation of anatomy is must to avoid potential damage to the ductal system; as being chances of having anomalies of gallbladder, cystic duct or cystic artery. During surgery meticulous dissection of the Callot's triangle and other structure is mandatory. The cholecystectomy is also recommended in double gallbladder. However, laparoscopic cholecystectomy which has now become the gold standard for cholecystectomy can be done safely in double gallbladder also [6].

CONCLUSION

We would like to highlight the importance of awareness of the possibility of a double gallbladder which could potentially be affected by any pathological processes commonly found in the hepatobiliary tract. Even though modern radiological techniques can sometimes fail to spot such abnormalities without a high index of suspicion, the focus should be on preoperative diagnosis of these variations as they can be easily missed at the time of surgery leading to intraoperative complications, persistent symptoms after surgery and often the need of performing further surgical procedures.

REFERENCES

1. Boyden EA. The accessory gallbladder - an embryological and comparative study of aberrant biliary vesicles occurring in man and domestic mammals. *Am J Anast.* 1926; 38: 177-231.
2. Mazziotti S, Minutoli F, Blandino A, Vinci S, Salamone I, Gaeta M. Gallbladder duplication: MR Cholangiography demonstration. *Abdom Imaging.* 2001; 26: 287-289.
3. Ozgen A, Akata D, Arta A, Demirkazik FB, Ozmen MN, Akhan O. Gallbladder duplication: imaging findings and differential considerations. *Abdom Imaging.* 1999; 24: 285-288.
4. Goiney RC, Schoenecker SA, Cyr DR, Shuman WP, Peters MJ, Cooperberg PL. Sonography of gallbladder duplication and differential consideration. *AJR Am J Roentgenol.* 1985; 145(2): 241-243.
5. Puneet MS, Satyendra KT, Agarwal S, Singh S, Khanna AK. Double Gallbladder. *The Internet Journal of Gastroenterology.* 2006; 4(2): [available online at http://www.ispub.com/journal/the_internet_journal_of_gastroenterology/volume_4_number_2_17/article/double_gallbladder.html]
6. Gigot J, Van Beers B, Goncette L, Etienne J, Collard A, Jadoul P, et al. Laparoscopic treatment of gallbladder duplication-A plea for removal of both gallbladder. *Surg Endosc.* 1997; 11: 479-482.